Sacroiliac Joint Pain

Paul Dreyfuss, MD, Susan J. Dreyer, MD, Andrew Cole, MD, and Keith Mayo, MD

Abstract

The sacroiliac joint is a source of pain in the lower back and buttocks in approximately 15% of the population. Diagnosing sacroiliac joint–mediated pain is difficult because the presenting complaints are similar to those of other causes of back pain. Patients with sacroiliac joint–mediated pain rarely report pain above L5; most localize their pain to the area around the posterior superior iliac spine. Radiographic and laboratory tests primarily help exclude other sources of low back pain. Magnetic resonance imaging, computed tomography, and bone scans of the sacroiliac joint cannot reliably determine whether the joint is the source of the pain. Controlled analgesic injections of the sacroiliac joint are the most important tool in the diagnosis. Treatment modalities include medications, physical therapy, bracing, manual therapy, injections, radiofrequency denervation, and arthrodesis; however, no published prospective data compare the efficacy of these modalities.

J Am Acad Orthop Surg 2004;12:255-265

The sacroiliac joint is an accepted source of pain in those with ankylosis spondylitis, those with metabolic disorders with involvement of the sacroiliac joint, and in those with osteoarthritis, infection, or tumors of the sacroiliac joint. The occurrence of isolated sacroiliac joint pain in the absence of these types of diseases is controversial. Mixter and Barr's 1934 study shifted the focus of attention from the sacroiliac joint to the disk. More recent fluoroscopically guided, contrast-enhanced injection techniques demonstrate that the sacroiliac joint is a source of primary low back pain and/or lower extremity pain in approximately 15% of patients with low back pain.[1,2] Understanding the anatomy, biomechanics, innervation, and pathophysiology of the sacroiliac joint can help in differentiating sacroiliac joint pain from muscular, discogenic, or degenerative lumbar spine symptoms. This is important because treatment modalities for the patient with sacroiliac joint symptoms differ from those for other causes of low back pain.

Anatomy

The sacroiliac joint becomes C-shaped by adulthood. The sacrum is wedged between the ilia. It is the largest axial joint in the human body, with a surface area of approximately 17.5 cm^2. It is considered to be a synovial joint even though 75% of its superior joint surface is not synovial. A fibrous capsule surrounds the sacroiliac joint. The anterior capsule and overlying ligament are relatively thin, and the anterior joint ligament blends into the iliolumbar ligament. A posterior sacroiliac joint capsule is often rudimentary or absent. The posterior border of the sacroiliac joint often is formed by the tough interosseous ligament. Accessory ligaments and the posterior sacroiliac, long posterior sacroiliac, sacrotuberous, and sacrospinous ligaments further support the sacroiliac joint (Fig. 1). The L5 ventral ramus and the lumbosacral trunk course anterior to the sacroiliac joint 2 cm below the pelvic brim; the S1 ventral ramus courses over the inferior anterior aspect of the sacroiliac joint.[3]

The morphology of the sacroiliac joint not only changes with age but it also varies greatly in size, shape, and contour from side to side as well as between individuals. The surface of the joint is flat until after puberty. By age 30, bony ridges are present on the articular surface of the ilium. In the third and fourth decades, elevations and depressions develop and enhance stability of the joint. The synovial articular surfaces erode; the synovial cleft narrows to 1 to 2 mm in individuals aged 50 to 70 years and to 0 to 1 mm in those aged more than 70 years. Ankylosis has been reported in individuals aged more than 50

Dr. Dreyfuss is Clinical Professor, Department of Rehabilitation Medicine, University of Washington, Seattle, WA. Dr. Dreyer is Assistant Professor, Department of Orthopaedic Surgery, and Assistant Professor, Department of Physical Medicine and Rehabilitation, Emory Spine Center, Emory University, Atlanta, GA. Dr. Cole is Associate Clinical Professor, Department of Rehabilitation Medicine, University of Washington, Seattle. Dr. Mayo is in private practice, Tacoma Regional Trauma Center, Tacoma, WA.

None of the following authors or the departments with which they are affiliated has received anything of value from or owns stock in a commercial company or institution related directly or indirectly to the subject of this article: Dr. Dreyfuss, Dr. Dreyer, Dr. Cole, and Dr. Mayo.

Reprint requests: Dr. Dreyfuss, Washington Interventional Spine Associates, Suite 260, 925 116th Avenue NE, Bellevue, WA 98004.

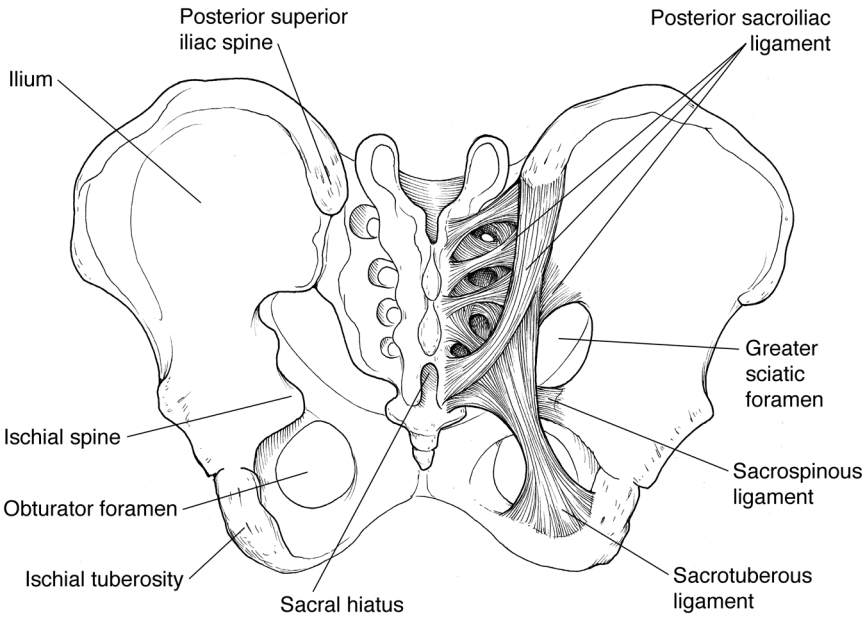

Figure 1 The sacroiliac joint and regional ligamentous anatomy.

years, especially men, although partial fibrous ankylosis and paraarticular synostosis are more common than is ossification.[4]

The sacroiliac joint is supported by the gluteus maximus and medius, erector spinae, latissimus dorsi, biceps femoris, psoas, piriformis, and oblique and tranversus abdominus muscles as well as by the thoracodorsal fascia. Muscles act indirectly on the sacroiliac joint and help deliver regional muscular forces to the pelvic bones. Innervation of these muscles is by T12-S4. Muscles adjacent to the sacroiliac joint (eg, gluteus maximus) have fibrous expansions that blend into the anterior and posterior joint ligaments. The gluteus maximus muscle, the piriformis, and the long head of the biceps femoris attach to the sacrotuberous ligament. The superficial thoracodorsal fascia has connecting fasciae to the gluteus maximus and minimus, iliotibial band, erector spinae, and osseous structures. Fascial reinforcement is greatest posteriorly.[4]

The synovial capsule and overlying ligaments of the sacroiliac joint contain unmyelinated free nerve endings that transmit pain and thermal sensation. The joint is innervated anteriorly by the L5-S2 ventral rami and the sacral plexus, and posteriorly by lateral branches from the S1-S4 dorsal rami.[5] Others report predominant innervation from the S1 dorsal ramus, with additional innervation from the S2-S4 dorsal rami but not from the ventral sacral plexus.[6,7]

Biomechanics

The sacroiliac joint, a triplanar shock absorber, forms a base for the spinal axis, transmits and dissipates upper trunk loads, and facilitates parturition. The joint can withstand six times more medially directed force than the lumbar spine can, but it fails at one-twentieth of the axial compression load and at half the axial torsion. If the sacroiliac joint becomes hypomobile, it may not be able to effectively dissipate forces. Axial compression and torsion may preferentially stress the weaker anterior joint capsule and ligaments.[4]

Sacroiliac joint motion is complex and probably multiaxial. Gliding, rotation, tilting, nodding (nutation), and translation likely occur. The two most common types of motion are nutation and counternutation. Nutation occurs with backward rotation of the ilium on the sacrum and counternutation, with forward rotation.[4] Radiographic stereophotogrammetry has demonstrated small amounts of rotation in the sacroiliac joint, usually limited to <4° of rotation and 1.6 mm of translation.[8] Sacroiliac joint motion progressively decreases in men aged between 40 and 50 years and in women aged more than 50 years.[4] Increased mobility occurs during pregnancy, but this motion has not been reliably quantified.

Compression of the sacrum with weight bearing creates a "keystone in an arch" effect: the greater the force through the sacrum, the greater the resistance. However, if this form closure were perfect, then no sacroiliac joint motion would occur. The indirect actions of the lumbopelvic muscles and ligaments, especially those whose fibers run perpendicular to the sacroiliac joint, produce compression and thus force closure of the joint. Cadaveric ligamentous sectioning studies have shown increased sacroiliac joint motion only after the interosseous ligament was severed. Sectioning the pubic symphysis, sacrospinous, or sacrotuberous ligaments had no effect.[9]

Lumbar spine, hip, and pubic symphysis motion and myofascial imbalances may indirectly affect sacroiliac joint motion. Whether a type or degree of "aberrant" joint motion causes pain has not been established. One study of stereophotogrammetry using physiologic positions showed no difference in joint motion between symptomatic and asymptomatic joints.[8]

Pathophysiology

The most common cause of sacroiliac joint pain is idiopathic and may

occur acutely or insidiously with cumulative trauma. Idiopathic sacroiliac joint pain may result from a change in the joint's position or mechanics. Theories of pain generation include ligamentous or capsular tension, extraneous compression or shear forces, hypomobility or hypermobility, aberrant joint mechanics, and myofascial or kinetic chain imbalances resulting in inflammation and pain.

Intra-articular sources of sacroiliac joint pain include osteoarthritis and infection. Joint infections usually occur from hematogenous spread. These infections typically are unilateral and may be caused by *Pseudomonas aeruginosa*, *Staphylococcus aureus*, *Cryptococcus* organisms, or *Myobacterium tuberculosis*. Predisposing factors include trauma, endocarditis, intravenous drug abuse, and immunosuppression. Infection may cause distention of the anterior joint capsule and irritate the lumbosacral nerve roots.

Extra-articular sources of sacroiliac joint pain include enthesis/ligamentous sprain and osseous sources such as insufficiency fracture. Extra-articular pain may be caused by primary enthesopathy. Also, ligamentous, tendinous, or fascial attachment and other cumulative soft-tissue injuries that may occur posterior to the dorsal aspect of the sacroiliac joint may be a source of discomfort. In young, healthy adults, fractures of the sacroiliac joint typically occur after major trauma, which also causes visceral and osseous injury. The risk of developing late sacroiliac joint pain may be slightly higher with lateral compression pelvic ring injuries than with other mechanisms.[10] Insufficiency fractures in the elderly osteoporotic patient may occur with little or no trauma and can be difficult to visualize on plain radiographs. Stress fractures have been reported in athletes and soldiers because of repetitive microtrauma caused by impact loading over long periods of frequent physical exertion.[4]

Inflammation of the sacroiliac joint may result from metabolic, traumatic, or arthritic causes. Sacroiliitis in inflammatory spondyloarthropathies is very common and present in virtually 100% of individuals with ankylosing spondylitis[11] (Fig. 2). Degenerative joint disease eventually affects all sacroiliac joints. Joint space narrowing, subchondral sclerosis, periarticular ankylosis, intra-articular gas formation, and osteophyte formation occur.

Metabolic processes that can affect the sacroiliac joint include calcium pyrophosphate crystal deposition disease, gout, ochronosis, hyperparathyroidism, renal osteodystrophy, and acromegaly. These processes may lead to early degeneration, inflammation, and pain. Primary sacroiliac tumors are rare; giant cell tumors, chondrosarcomas, and synovial villoadenomas are the most common neoplasms. Metastases to the pelvis account for 40% of all osseous metastasis, second only to those of the spine.

Iatrogenic instability may be caused by overzealous bone harvesting for grafts or from pelvic resection of tumors. The bone harvesting technique may cause secondary mechanical injury to the sacroiliac joint, resulting in intra-articular joint pain. Additionally, extra-articular sacroiliac joint pain may result from periosteal, ligamentous, or enthesis irritation or cluneal nerve injury from the bone harvest process.

The third trimester of pregnancy results in hypermobility of the sacroiliac joint because of increased levels of estrogen and relaxin that cause the soft tissues supporting the joint to loosen. This laxity may predispose the sacroiliac joint ligaments to painful sprain. The mechanical trauma of childbirth also may cause joint pain. Lumbar spine fusion or hip arthrodesis may transfer additional forces to the sacroiliac joint, creating cumulative stress and pain. Joint pain may coexist with discogenic pain, especially at L5-S1. This may be because of a biomechanical interdependence or central hypersensitivity.

Figure 2 Severe bilateral arthropathy of the sacroiliac joint resulting from ankylosing spondylitis.

Differential Diagnosis

Intrinsic disk disease, nerve root compression, zygapophyseal joint pain, primary or secondary myofascial syndromes, and symptoms from nonspinal structures all may mimic sacroiliac joint pain because of their overlapping pain referral patterns. Clinically distinguishing primary joint pain from other spinal conditions can be difficult. Inflammatory disorders of the sacroiliac joint, including ankylosing spondylitis and Reiter's syndrome, often are diagnosed clinically (Table 1). Appropriate radiographic abnormalities and laboratory findings, including a positive HLA-B27 test and elevated erythrocyte sedimentation rate, confirm the diagnosis. Painful nonspinal disorders such as gastrointestinal, genitourinary, gynecologic, and hip joint dysfunction may be distinguished on clinical grounds and with appropriate ancillary testing.

Diagnostic Evaluation

Pain Patterns

Pathology in the sacroiliac joint causes referred pain to an area just inferior to the ipsilateral posterior superior iliac spine.[1,2,12-15] This referral area (approximately 3 × 10 cm) is common to other sources of spinal pain. Only 4% of patients with sacroiliac joint pain mark any pain above L5 on self-reported pain drawings.[12] Furthermore, referral of pain into various locations of the lower extremity does not distinguish sacroiliac joint pain from other pain states.[2,12] For example, in one study,[2] pain below the knee and into the foot was as common with sacroiliac joint pain as with other sources. In another study,[15] pain referral zones were evaluated in 54 patients in whom the sacroiliac joint was established as the source of symptoms by intra-articular blocks. Ninety-four percent of the patients had pain in the buttocks; 48%, in the thigh; 28%, the lower leg; 13%, foot/ankle; 14%, groin; and 2%, abdomen (Fig. 3).

Physical Examination

No specific physical examination tests have been validated that accurately identify a painful sacroiliac joint. Physical examination is used to exclude other diagnostic possibilities, including radiculopathy, tumor, and inflammatory spondyloarthropathies. Physical examination should include a thorough neurologic examination with evaluation of straight leg raising and assessment of pain and motion loss throughout the lower thoracic and lumbar spine. The hip joint should be thoroughly tested and palpated for focal zones of soft-tissue or osseous pain in the lumbosacral-pelvic region. The patient should point to the area of maximal pain, and its location should be noted. Focal areas of tenderness along the sacroiliac joint line and in the sacral sulcus should be evaluated. (The sacral sulcus is the soft-tissue depression appreciated just medial to the posterior superior iliac spine.)

Patients with only sacroiliac joint pain typically are neurologically intact, but they may demonstrate pain-inhibited weakness, subjective nondermatomal extremity sensory loss, and other distal sensory complaints. A false-positive straight leg raise test may occur when the affected leg is elevated to approximately 60° because false dural tension symptoms are caused by sacroiliac joint motion at this degree of elevation.

Current methods used for testing the sacroiliac joint lack scientific validity. These include provocative testing (Patrick's and Gaenslen's tests), motion demand tests (articular spring tests), true and functional leg-length determinations, testing for strength and length soft-tissue imbalances, ligament tension tests, and hip rotation

Table 1
Adult Seronegative Spondyloarthropathies: Disorders With the Highest Degree of Sacroiliac Joint Involvement[11]

Characteristic	Ankylosing Spondylitis	Reactive Arthritis (Reiter's Syndrome)	Psoriatic Arthropathy
HLA-B27 frequency	90%	60% to 80%	50%
Sacroiliitis	Almost 100%	<50%	Approximately 20%
Symmetry of sacroiliitis	Symmetric	Asymmetric	Asymmetric
Typical age of onset	Adult <40 yr	Young to middle aged	Young to middle aged
Peripheral joint involvement	Approximately 25%	Approximately 90%	Approximately 95%
Type of onset	Gradual	Acute	Variable
Eye involvement	30%	Common	Occasional
Skin or nail involvement	None	Common	Almost 100%
Infectious agents as triggers	Unknown	Yes	Unknown
Sex ratio	M:F = 3:1	Mostly males	Males = Females

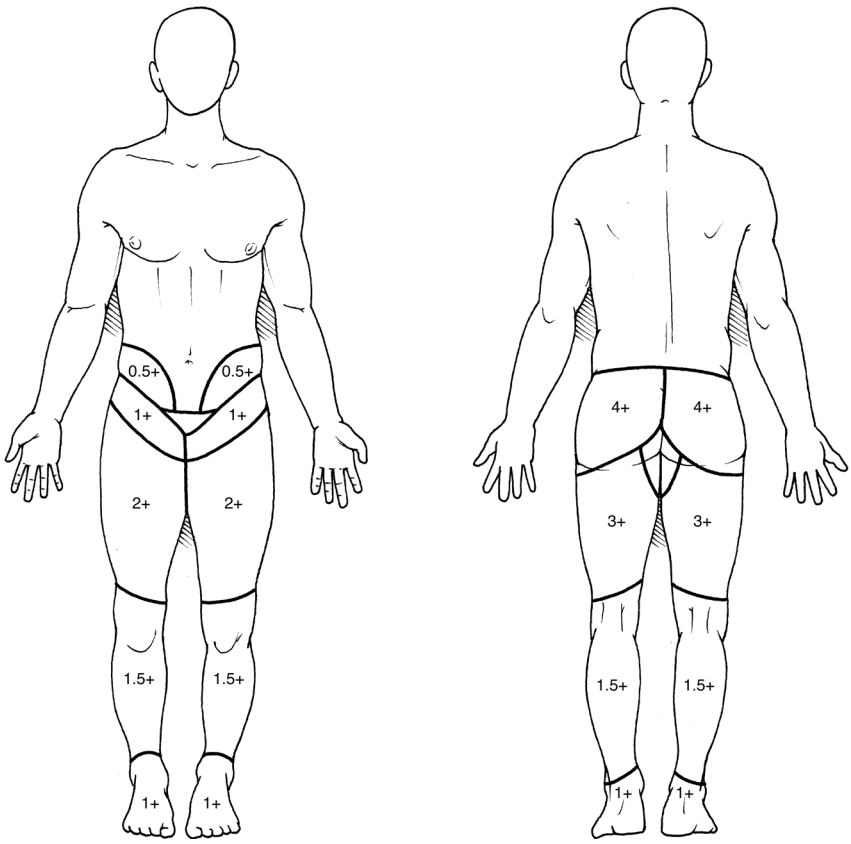

Figure 3 Density of referral zones for sacroiliac joint pain. 0.5+ is the least common referral zone, 4+ the most common.

testing. Of four studies[1,2,12,13] that compared the accuracy of various physical examination maneuvers to that of diagnostic, fluoroscopically guided, contrast-enhanced, intra-articular sacroiliac joint injections, none validated stand-alone use of the maneuvers (Table 2). All of these tests and maneuvers remain unvalidated: an increase or decrease in pain with any of the following—flexion or extension, rotation, ipsilateral or contralateral flexion, quadrant loading, straight leg raising, sitting, standing, walking, sacroiliac joint compression, sacroiliac joint distraction, Gaenslen's test, Patrick's test, sacral sulcus tenderness, the posterior superior iliac spine identified as the site of maximal pain, midline sacral thrust, thigh thrust, resisted external rotation of the hip, pubic symphysis tenderness, Gillet's test, "restriction" in the superior sacroiliac joint pole, and abnormal sitting posture.[18,19]

Dreyfuss et al[12] demonstrated that, despite poor specificity, the highest sensitivity occurred with sacral sulcus tenderness (89%). Sacral sulcus tenderness thus may serve as a reasonable screening test for sacroiliac joint pain. However, the poor specificity of this test implies that patients with other sources of low back pain also may have tenderness of the sacral sulcus; a negative sacral sulcus test misses approximately 11% of those with sacroiliac joint pain. Maximal pain below L5, together with pointing to the posterior superior iliac spine or sacral sulcus tenderness, has the highest positive predictive value (60%).[12,13] This combination of features is not diagnostic, but no other test or combination of tests has yielded a higher positive predictive value.

Radiographic Examinations

No imaging studies consistently provide findings that are helpful to diagnose primary sacroiliac joint pain. Computed tomography (CT), magnetic resonance imaging (MRI), and bone scan are done predominantly to exclude other causes of pain rather than to diagnose idiopathic sacroiliac joint pain. CT of the sacroiliac joint has limited clinical value because of poor sensitivity and specificity compared with diagnostic intra-articular sacroiliac joint injections.[20] MRI yields excellent images of soft tissue for tumor identification and can isolate early inflammatory changes in spondyloarthropathies. Increased uptake on bone scan helps identify stress fractures, infection, inflammatory arthritis, and primary or metastatic tumors.

As in other synovial joints, degenerative changes, which progress with age, may occur in the sacroiliac joints of asymptomatic individuals. At least 24.5% of asymptomatic patients older than 50 years have abnormal joints on plain radiographs.[4] No studies have compared plain radiographs or MRI to fluoroscopically guided, contrast-enhanced sacroiliac joint injections. The specificity of bone scans is 90%, with a sensitivity of only 12% to 46% in diagnosing sacroiliac joint pain.[16] The positive predictive value of bone scans is 86% and negative predictive value, 72%.[17]

Congenital (eg, bladder extrophy) and acquired (ie, traumatic) displacement and instability may be significant in the pathogenesis of sacroiliac joint pain. Baseline imaging studies in patients with these conditions should include plain anteroposterior pelvic and inlet and outlet radiographs. When instability is suspected, single leg stance pelvic (stork) views also should be obtained. When deformity correction is considered, additional imaging should include

Table 2
Sensitivity and Specificity of Major Diagnostic Tests Used to Identify Those With Intra-articular Sacroiliac Joint Pain[1,2,13,15-17]

Test	Sensitivity	Specificity
Sacroiliac joint pain	+ + + +	+
Groin pain	+	+ + +
Buttock pain	+ + + +	+
Indicating posterior superior iliac spine as pain source	+ + + +	+ +
Abnormal sitting posture	+	+ + + +
Pain lessens with NSAIDs	+ +	+ +
Pain lessens with exercise	+ +	+ + + +
Pain lessens with manipulation	+ + +	+ + + +
Gillet's test	+ +	+ + +
Patrick's test	+ + +	+
Gaenslen's test	+ + +	+ +
Sacral sulcus tenderness	+ + + +	+
Midline sacral thrust	+ + +	+ +
Bone scan	+ +	+ + + +
Computed tomography	+ + +	+ + +

Sensitivity/specificity scale: + = 0-25%; + + = 26%-50%; + + + = 51%-75%; + + + + = 76%-100%

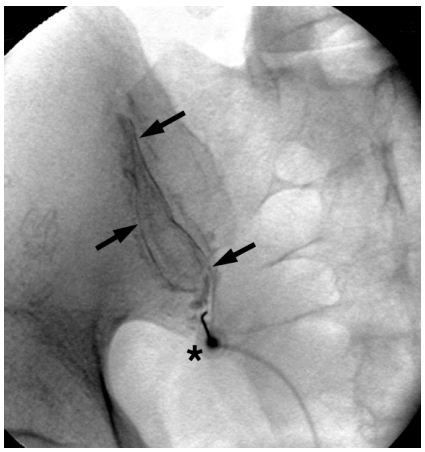

Figure 4 Anteroposterior arthrogram of the sacroiliac joint without extravasation. The asterisk indicates the needle; arrows indicate the contrast medium in the joint.

CT with sagittal and coronal views and three-dimensional reconstructions.[21] In clinical settings in which a coexisting lumbar radiculopathy or traumatic lumbosacral plexopathy appears to exist, electrodiagnostic studies (nerve conduction velocity, electromyography, or somatosensory evoked potential) may provide diagnostic and therapeutic information.

Diagnostic Injections

Because of limitations of the history, physical examination, and imaging modalities, controlled fluoroscopically guided or CT-guided, contrast-enhanced injections are the only method for definitively diagnosing or excluding the sacroiliac joint as a source of pain (Fig. 4, Table 3). Sacroiliac joint blocks are indicated when the patient has sacral sulcus tenderness or shows discomfort over the joint on pain drawings; otherwise, the likelihood of sacroiliac joint pain is very low.

Ideally, for a test to be considered diagnostic, complete relief of the pain emanating from the sacroiliac joint should be achieved. However, residual pain from the procedure itself may occur. Published studies have used ≥75% pain relief as diagnostic of sacroiliac joint–mediated pain and ≤50% relief as not diagnostic, with 51% to 74% relief considered equivocal. If the clinical situation warrants, an apparently positive response should be confirmed with a subsequent control block.

The maximum volume that should be injected into the sacroiliac joint is 2.5 mL, although the amount often is limited to 2.0 mL. Excessive injectate can leak from the anterior capsule onto regional neural structures and limit diagnostic specificity. Analysis by CT-arthrography has shown that the average joint volume is 1.08 mL in symptomatic patients (range, 0.8 to 2.5 mL; SD, 0.29 mL).[22] Additional evaluation in asymptomatic subjects has revealed an average joint volume of up to 1.6 mL.[14] Fortin et al [23] reported escape of injectate in 61% of 76 sacroiliac joints, as determined by fluoroscopy with CT analysis of contrast medium flow. Twenty-seven percent of extravasations communicated with nearby neural structures, even when the injected volume was appropriate. Postinjection anteroposterior, lateral, and oblique imaging should be evaluated to

Table 3
Diagnostic Criteria for Identifying Idiopathic Intra-articular Sacroiliac Joint Pain[1,2,4,12,13]

- No neurologic deficits
- No dural tension signs
- No laboratory, imaging, or clinical evidence of medical causes of sacroiliac joint pain
- Maximal pain below L5
- No evidence of lumbar pain generators (if indicated, maximally secured with negative zygapophyseal joint blocks and diskography)
- At least 75% relief with controlled, dual fluoroscopically guided, contrast-enhanced intra-articular sacroiliac joint injections

assess the target specificity of the injection and to avoid an inappropriate diagnosis that can occur from anesthetization of nearby neural structures.[23] In addition, radiographic (fluoroscopic) visualization ensures accurate joint injection so that diagnostic sensitivity and specificity are maximized. In a recent prospective study of sacroiliac joint injections performed without image guidance (ie, "blind"), intra-articular injection of the joint occurred in only 22% of patients (8/37). Epidural flow was seen 24% of the time and dorsal sacral foraminal flow, 44% of the time.[24]

The risk of false-positive responses applies to all diagnostic blocks for reasons not inherent in the volume or dispersion of medication. Patients may report relief of pain for reasons other than the action of the injected agent. To avoid or reduce the risk of false-positive diagnosis based on the results of these blocks, they should be subjected to some form of control, such as injection of a placebo agent (eg, saline) under double-blind controlled conditions. However, doing so requires informed consent, and patients or their advocates might object to undergoing a sham procedure. An alternative form of control, if needed, is to anesthetize the joint on separate occasions using agents with different durations of action. This technique, known as comparative local anesthetic blocks, has not been validated for sacroiliac intra-articular blocks, although it has been used to determine the prevalence of sacroiliac joint pain.[1] Comparative local anesthetic blocks are useful when repeat blocks fail to relieve a patient's pain because the first response was a false positive.

Management

Most research on sacroiliac joint pain has focused on anatomy, biomechanics, and diagnostic strategies, not on diagnosis-specific management strategies. Techniques to treat joint pain include medications, physical modalities, activity modification, education, exercise-based therapy, aerobic conditioning, bracing, manual therapy, injections, prolotherapy, neuroaugmentation, viscosupplementation, radiofrequency neurotomy (Fig. 5), and arthrodesis (Fig. 6). The only randomized controlled trials published to date for the treatment of sacroiliac joint pain involve fluoroscopically guided, contrast-enhanced, intra-articular corticosteroid injections in individuals with seronegative spondyloarthropathies. No randomized trials have been published regarding the efficacy of treatment methods for idiopathic joint pain. Results have been reported for noncontrolled studies of manipulation for presumed idiopathic sacroiliac joint pain and for noncontrolled studies of intra-articular corticosteroid injections, radiofrequency neurotomy, and arthrodesis in patients with pain established by diagnostic sacroliliac joint blocks.

Treatment goals include decreasing pain and improving function by restoring balance in joint kinematics and function, establishing lumbopelvic–lower extremity muscular length and strength balance, and correcting lumbopelvic-hip mechanics. Correcting soft-tissue irritability is important, as is establishing a prevention program and retraining optimal movement patterns through dynamic postural control. This approach addresses articular, muscular, fascial, and ligamentous components in the lumbopelvic-hip complex.

Diagnosis-driven management plans should be developed on an individual basis. For example, manipulation is contraindicated in the patient with an insufficiency sacral fracture. Individuals with intra-articular pain from osteoarthritis may benefit from an intra-articular, fluoroscopically guided, contrast-enhanced sacroiliac joint injection and exercise-based therapy. A lumbar fusion may resolve concomitant intrinsic L5-S1 disk pain, but it also will increase the forces transferred to the sacroiliac joint. Thus, the L5-S1 pain may resolve, but the joint pain may worsen.

Medications

The basic principles of medical pain management apply, including the use of nonsteroidal anti-inflammatory drugs, nonopiate analgesics, opiates, antidepressants, and other adjunctive medications. Newer agents such as protease inhibitors (eg, etanercept) have been shown to reduce pain and inflammation in inflammatory spondyloarthropathy.

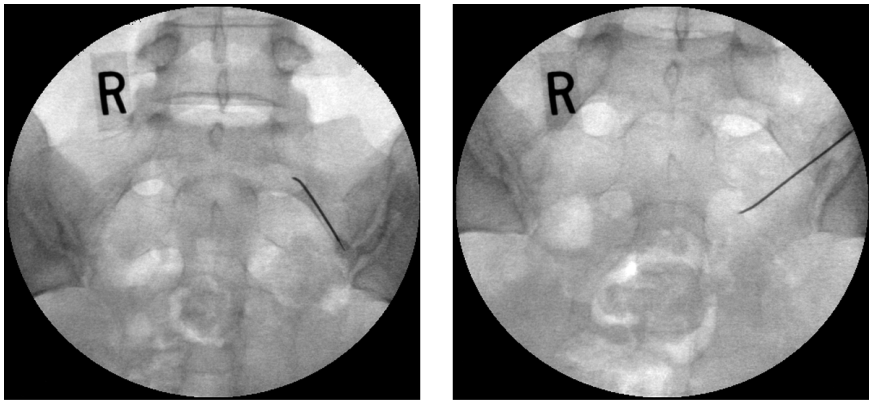

Figure 5 Anteroposterior radiographs of a sacroiliac joint radiofrequency neurotomy procedure. **A,** One of the lateral branches of the S1 dorsal ramus. **B,** One of the lateral branches of the S2 dorsal ramus.

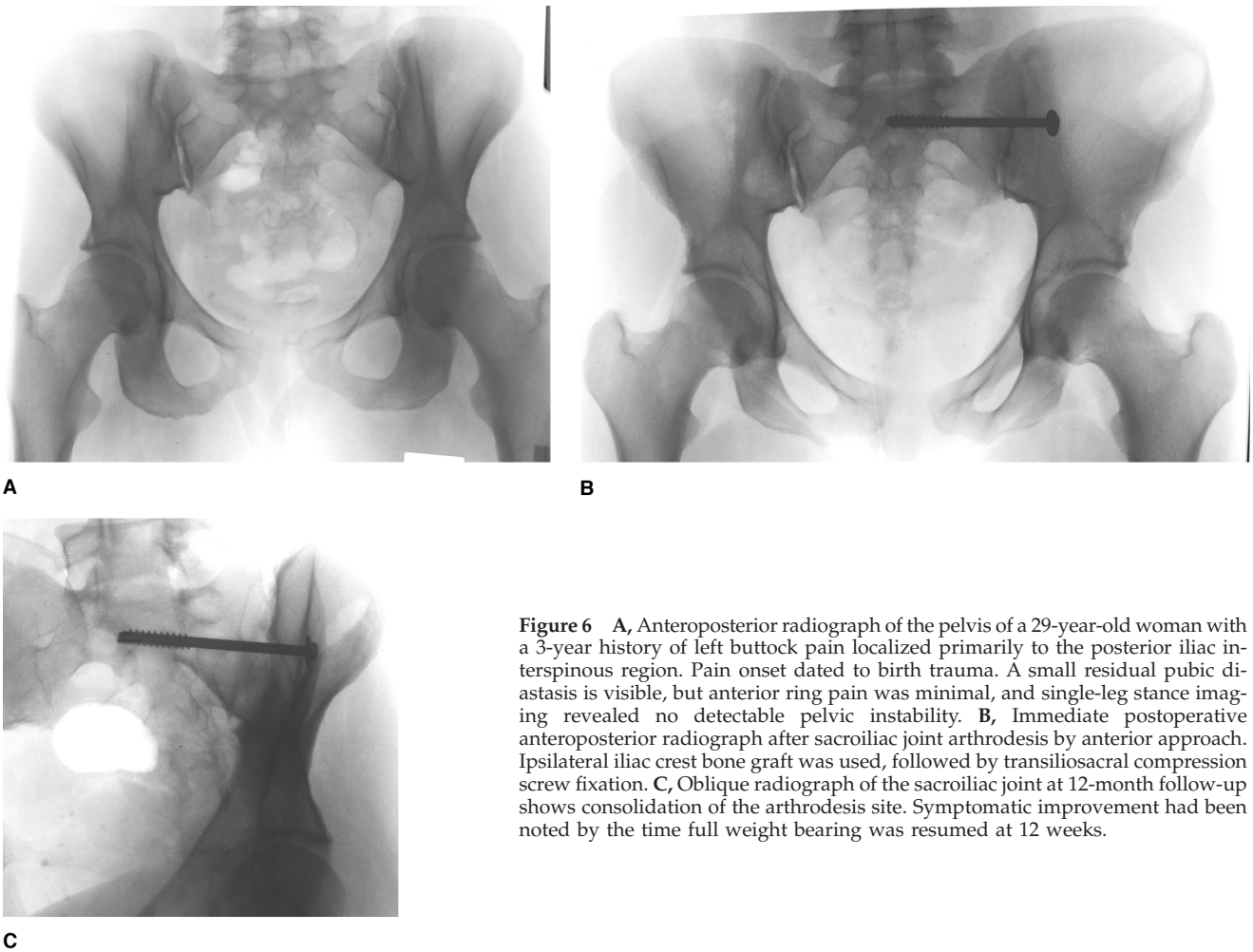

Figure 6 **A,** Anteroposterior radiograph of the pelvis of a 29-year-old woman with a 3-year history of left buttock pain localized primarily to the posterior iliac interspinous region. Pain onset dated to birth trauma. A small residual pubic diastasis is visible, but anterior ring pain was minimal, and single-leg stance imaging revealed no detectable pelvic instability. **B,** Immediate postoperative anteroposterior radiograph after sacroiliac joint arthrodesis by anterior approach. Ipsilateral iliac crest bone graft was used, followed by transiliosacral compression screw fixation. **C,** Oblique radiograph of the sacroiliac joint at 12-month follow-up shows consolidation of the arthrodesis site. Symptomatic improvement had been noted by the time full weight bearing was resumed at 12 weeks.

Physical Therapy

The general principles of rehabilitation apply to individuals with sacroiliac joint pain. Use of modalities should be limited and are most appropriate during the acute phase. Flexibility and strength deficits should be identified and corrected. Education in and training of proper body mechanics and posture are essential, as is aerobic conditioning. Early mobilization and physiologic stresses promote soft-tissue healing while preventing the deleterious effects of immobilization, including atrophy, weakening of ligaments, and impaired joint nutrition. In particular, certain muscles should be specifically strengthened because of their ligamentous and fascial attachments to the sacroiliac joint complex; these include the hamstrings, gluteus maximus and medius, piriformis, erector spinae, latissimus dorsi, and iliacus muscles.

Braces

Braces do not protect against injury, but they may provide some pain relief and/or proprioceptive feedback. Pelvic belts, most effectively worn directly superior to the greater trochanter, can help decrease sacroiliac joint motion by approximately 30%.[25] Rapid weaning avoids psychological dependence and prevents decreased soft-tissue flexibility and potential muscular weakness.

Manual Therapy/Manipulation

Manual methods for correcting sacroiliac joint dysfunction fall into three broad categories: direct mobilization, direct manipulation, and indirect techniques (eg, muscle energy). No one discipline (osteopathic, chiropractic, or manual physical therapy) has been shown to be superior to another. If a patient does not respond to treatment 2 to 3 times per week over a 3- to 4-week period (maximum, 12 sessions), then other treatment techniques should be considered. Ideally, as manual therapy reduces pain, a structured exercise program is initiated to promote restoration of soft-tissue flexibility, strength, and balance.

The physiologic basis for improvement after mobilization and/or manipulation of the sacroiliac joint is unknown. In a radiographic stereophotogrammetric analysis study of osseous positions before and after joint manipulation in 10 patients with presumed sacroiliac joint pain, no positional change of the sacrum or ilium was seen, suggesting that no measurable mechanical change occurs with manipulation.[26] However, in an observational prospective study, 69 patients with sacroiliac joint pain, based on history and physical examination, were treated with joint manipulation. After 2 weeks, 71% reported feeling "considerably better" or "pain free."[27] No manual therapy studies exist for patients with established rather than presumed sacroiliac joint pain.

Injections

Clinical suspicion of sacroiliac joint pain should be confirmed with diagnostic and potentially therapeutic injection procedures only after a minimum of 4 weeks of appropriate, directed, noninvasive conservative care. If pain substantially inhibits work or progress in physical and/or manual therapy, earlier use of an injection procedure may be diagnostic and may provide therapeutic benefit.

Poor target specificity of blind sacroiliac joint injections makes their use unacceptable.[24] In most controlled and observational outcome studies, intra-articular sacroiliac joint corticosteroid injections provided therapeutic benefit for sacroiliitis in patients with spondyloarthropathy.[28-32] However, there are no controlled trials demonstrating benefit for other causes of joint pain. In one retrospective, uncontrolled case series of 20 patients with documented idiopathic sacroiliac joint pain, use of intra-articular corticosteroid provided modest relief.[33] Uncontrolled observational reports suggest that some benefit occurs from the use of extra-articular corticosteroids for presumed extra-articular sacroiliac joint pain.

After an intra-articular sacroiliac joint injection, the patient should be provided with a pain log that uses a visual analog scale. Patients self-monitor the level of pain each hour for 6 hours, then daily for the following week. This monitoring helps distinguish between anesthetic and steroid phase relief (ie, the diagnostic and therapeutic phases of the injection). If ≥75% short-term relief is noted, then physical and/or manual therapy should be considered.[34] If <75% relief is reported, other sources of pain should be considered (Table 3).

Prolotherapy

No studies address the efficacy of prolotherapy for managing sacroiliac joint pain, although two randomized controlled trials have reported superior results with prolotherapy over sham injections for chronic nonspecific low back pain.[35,36] Prolotherapy is not widely accepted, but proponents believe that certain agents (eg, a dextrose/glycerine/phenol/lidocaine solution) injected at the enthesis of the ligamentous complex surrounding the sacroiliac joint creates an inflammatory response. Inflammation may cause fibroblastic migration as well as ligamentous and fibril widening and strengthening because of collagen proliferation. Strengthening the ligamentous supporting system may allow the sacroiliac joint to function properly in cases of presumed ligamentous weakening or laxity.

Neuroaugmentation and Viscosupplementation

No controlled studies exist on neuroaugmentation and viscosupplementation techniques for sacroiliac joint pain. Isolated case reports suggest that partial pain relief follows implantation of a nerve stimulator at the third sacral nerve root[37] or after intra-articular joint injection of hylan G-F 20.[38] However, whether these results are reproducible has yet to be determined.

Radiofrequency Neurotomy

Radiofrequency denervation should be considered only after other, less invasive methods of care have been exhausted and the diagnosis is proven. Radiofrequency neurotomy of the L5 dorsal ramus, its branches to the sacroiliac joint, and the lateral branches of the S1-S3 dorsal rami may be performed for chronic joint pain. (Theoretically, this procedure would be more effective if the sacroiliac joint received a predominantly, if not exclusively, dorsal innervation.) Radiofrequency neurotomy likely is more effective for extra-articular than intra-articular joint pain because there is no known anterior innervation to the dorsal sacroiliac joint ligamentous complex. Although blockade of the medial branches in the lumbar spine is accurate, reproducible, and prognostic, blockade of the sacral lateral branches has not shown similar results because of fascial and ligamentous restraints, which limit spread of injected agents. Therefore, sacral lateral branch blocks should not be done to determine which patients are suitable candidates for radiofrequency neurotomy. The most reasonable selection criteria seem to be confirmatory intra-articular sacroiliac joint blocks and exclusion of lumbar pain sources by zygapophyseal joint blocks and diskography. In an initial retrospective audit, 14 patients with negative lumbar medial branch blocks and two positive extra-articular ligamentous blocks underwent sensory stimulation-guided sacroiliac joint radiofrequency neurotomy. At 6-month follow-up, 64% had >50% reduction of pain.[39]

Arthrodesis

Arthrodesis for sacroiliac joint pain in the absence of joint destruction from infection, trauma, or other causes of severe instability remains controversial. Arthrodesis should be considered only in patients with joint pain proven by controlled diagnostic anesthetic blocks and without any pain sources in the lumbar spine. It

also should be reserved for those who continue to have disabling symptoms that have not responded to aggressive conservative care. Preoperative assessment should eliminate other sites of pelvic ring pain and associated pelvic instability. The presence of associated symphyseal symptoms may require stabilization or arthrodesis of the symphysis in addition to arthrodesis of the sacroiliac joint. No comparison studies of successful fusion rates or clinical outcomes exist for the various arthrodesis techniques. Reports of small, retrospective series reveal generally positive results.[40-43] However, pain relief is rarely complete, and postoperative recovery can be protracted.

Surgical access for sacroiliac joint arthrodesis can be achieved anteriorly or posteriorly, although the anterior approach has several advantages (Fig. 6). Most importantly, it provides direct exposure of the ventral and cranial synovial portion of the sacroiliac complex without sacrificing any of the primary soft-tissue (ligamentous) stabilizers. A large portion of the joint can be directly débrided, and recesses can be prepared for bridging cancellous autograft obtained from the already exposed ipsilateral iliac crest. Stabilization follows, with spanning plates and/or transiliosacral screws An additional benefit of the anterior approach is that symphyseal instability or pain can be addressed without position change. Finally, the wounds are not dependent; thus, the initial postoperative morbidity usually is less than with posterior approaches. Postoperative management includes protected (20 kg) weight bearing for 8 to 12 weeks. Radiographic consolidation of the arthrodesis usually is slow and may require CT for accurate assessment.

Summary

The sacroiliac joint is a potential source of low back and referred lower extremity pain; approximately 15% of chronic low back pain is attributable to the sacroiliac joint. However, no noninvasive pathognomonic findings distinguish sacroiliac joint–mediated pain from other sources of spine pain. Sacroiliac joint pain can be confirmed by controlled, fluoroscopically guided or CT-guided, contrast-enhanced anesthetic injection procedures. Treatment modalities include medications, physical therapy, bracing, manual therapy, injections, radiofrequency denervation, and arthrodesis. To help guide selection of the most appropriate and cost-effective treatment methods, controlled prospective studies comparing management options to the natural history of sacroiliac pain are needed.

References

1. Maigne JY, Aivaliklis A, Pfefer F: Results of sacroiliac joint double block and value of sacroiliac pain provocation tests in 54 patients with low back pain. *Spine* 1996;21:1889-1892.
2. Schwarzer AC, Aprill CN, Bogduk N: The sacroiliac joint in chronic low back pain. *Spine* 1995;20:31-37.
3. Ebraheim NA, Lu J, Biyani A, Huntoon M, Yeasting RA: The relationship of lumbosacral plexus to the sacrum and the sacroiliac joint. *Am J Orthop* 1997;26: 105-110.
4. Dreyfuss P, Cole AJ, Pauza K: Sacroiliac joint injection techniques. *Phys Med Rehabil Clin N Am* 1995;6:785-813.
5. Ikeda R: Innervation of the sacroiliac joint: Macroscopical and histological studies [Japanese]. *Nippon Ika Daigaku Zasshi* 1991;58:587-596.
6. Fortin JD, Kissling RO, O'Connor BL, Vilensky JA: Sacroiliac joint innervation and pain. *Am J Orthop* 1999;28:687-690.
7. Grob KR, Neuhuber WL, Kissling RO: Innervation of the sacroiliac joint of the human [German]. *Z Rheumatol* 1995;54: 117-122.
8. Sturesson B, Selvik G, Uden A: Movements of the sacroiliac joints: A roentgen stereophotogrammetric analysis. *Spine* 1989;14:162-165.
9. Vrahas M, Hern TC, Diangelo D, Kellam J, Tile M: Ligamentous contributions to pelvic stability. *Orthopedics* 1995;18:271-274.
10. Pohlemann T, Tscherne H, Baumgartel F, et al: Pelvic fractures: Epidemiology, therapy and long-term outcome. Overview of the multicenter study of the Pelvis Study Group [German]. *Unfallchirurg* 1996;99:160-167.
11. Schumacher HR Jr, Klippel JH, Koopman WJ (eds): *Primer on the Rheumatic Diseases*, ed 10. Atlanta, GA: Arthritis Foundation, 1993, pp 151-163.
12. Dreyfuss P, Michaelsen M, Pauza K, McLarty J, Bogduk N: The value of medical history and physical examination in diagnosing sacroiliac joint pain. *Spine* 1996;21:2594-2602.
13. Slipman CW, Sterenfeld EB, Chou LH, Herzog R, Vresilovic E: The predictive value of provocative sacroiliac joint stress maneuvers in the diagnosis of sacroiliac joint syndrome. *Arch Phys Med Rehabil* 1998;79:288-292.
14. Fortin JD, Dwyer AP, West S, Pier J: Sacroiliac joint: Pain referral maps upon applying a new injection/arthrography technique. I: Asymptomatic volunteers. *Spine* 1994;19:1475-1482.
15. Slipman CW, Jackson HB, Lipetz JS, Chan KT, Lenrow D, Vresilovic EJ: Sacroiliac joint pain referral zones. *Arch Phys Med Rehabil* 2000;81:334-338.
16. Slipman CW, Sterenfeld EB, Chou LH, Herzog R, Vresilovic E: The value of radionuclide imaging in the diagnosis of sacroiliac joint syndrome. *Spine* 1996; 21:2251-2254.
17. Maigne JY, Boulahdour H, Chatellier G: Value of quantitative radionuclide bone scanning in the diagnosis of sacroiliac joint syndrome in 32 patients with low back pain. *Eur Spine J* 1998;7:328-331.
18. van der Wurff P, Meyne W, Hagmeijer RH: Clinical tests of the sacroiliac joint. *Man Ther* 2000;5:89-96.
19. Freburger JK, Riddle DL: Using published evidence to guide the examination of the sacroiliac joint region. *Phys Ther* 2001;81:1135-1143.
20. Elgafy H, Semaan HB, Ebraheim NA, Coombs RJ: Computed tomography findings in patients with sacroiliac pain. *Clin Orthop* 2001;382:112-118.
21. Matta JM, Dickson KF, Markovich GD: Surgical treatment of pelvic nonunions and malunions. *Clin Orthop* 1996;329: 199-206.

22. Fortin JD, Tolchin RB: Abstract: Sacroiliac joint provocation and arthrography. *Arch Phys Med Rehabil* 1993;74:1259.
23. Fortin JD, Washington WJ, Falco FJE: Three pathways between the sacroiliac joint and neural structures. *AJNR Am J Neuroradiol* 1999;20:1429-1434.
24. Rosenberg JM, Quint DJ, de Rosayro AM: Computerized tomographic localization of clinically-guided sacroiliac joint injections. *Clin J Pain* 2000;16:18-21.
25. Vleeming A, Buyruk HM, Stoeckart R, Karamursel S, Snijders CJ: An integrated therapy for peripartum pelvic instability: A study of the biomechanical effects of pelvic belts. *Am J Obstet Gynecol* 1992;166:1243-1247.
26. Tullberg T, Blomberg S, Branth B, Johnsson R: Manipulation does not alter the position of the sacroiliac joint: A roentgen stereophotogrammetric analysis. *Spine* 1998;23:1124-1128.
27. Kirkaldy-Willis WH, Cassidy JD: Spinal manipulation in the treatment of low-back pain. *Can Fam Physician* 1985;31: 535-540.
28. Braun J, Bollow M, Seyrekbasan F, et al: Computed tomography guided corticosteroid injection of the sacroiliac joint in patients with spondyloarthropathy with sacroiliitis: Clinical outcome and followup by dynamic magnetic resonance imaging. *J Rheumatol* 1996;23:659-664.
29. Bollow M, Braun J, Taupitz M, et al: CT-guided intraarticular corticosteroid injection into the sacroiliac joints in patients with spondyloarthropathy: Indication and follow-up with contrast-enhanced MRI. *J Comput Assist Tomogr* 1996;20:512-521.
30. Luukkainen R, Nissilä M, Asikainen E, et al: Periarticular corticosteroid treatment of the sacroiliac joint in patients with seronegative spondylarthropathy. *Clin Exp Rheumatol* 1999;17:88-90.
31. Maugars Y, Mathis C, Berthelot JM, Charlier C, Prost A: Assessment of the efficacy of sacroiliac corticosteroid injections in spondylarthropathies: A double-blind study. *Br J Rheumatol* 1996;35:767-770.
32. Hanly JG, Mitchell M, MacMillan L, Mosher D, Sutton E: Efficacy of sacroiliac corticosteroid injections in patients with inflammatory spondyloarthropathy: Results of a 6 month controlled study. *J Rheumatol* 2000;27:719-722.
33. Slipman CW, Lipetz JS, Plastaras CT, et al: Fluoroscopically guided therapeutic sacroiliac joint injections for sacroiliac joint syndrome. *Am J Phys Med Rehabil* 2001;80:425-432.
34. Dreyfuss P, Michaelsen M, Horne M: MUJA: Manipulation under joint anesthesia/analgesia. A treatment approach for recalcitrant low back pain of synovial joint origin. *J Manipulative Physiol Ther* 1995;18:537-546.
35. Klein RG, Eek BC, DeLong WB, Mooney V: A randomized double-blind trial of dextrose-glycerine-phenol injections for chronic, low back pain. *J Spinal Disord* 1993;6:23-33.
36. Ongley MJ, Klein RG, Dorman TA, Eek BC, Hubert LJ: A new approach to the treatment of chronic low back pain. *Lancet* 1987;2:143-146.
37. Calvillo O, Esses SI, Ponder C, D'Agostino C, Tanhui E: Neuroaugmentation in the management of sacroiliac joint pain: Report of two cases. *Spine* 1998;23:1069-1072.
38. Srejic U, Calvillo O, Kabakibou K: Viscosupplementation: A new concept in the treatment of sacroiliac joint syndrome. A preliminary report of four cases. *Reg Anesth Pain Med* 1999;24:84-88.
39. Yin W, Willard F, Carreiro J, Dreyfuss P: Sensory stimulation-guided sacroiliac joint radiofrequency neurotomy: Technique based on neuroanatomy of the dorsal sacral plexus. *Spine* 2003;28: 2419-2425.
40. Belanger TA, Dall BE: Sacroiliac arthrodesis using a posterior midline fascial splitting approach and pedicle screw instrumentation: A new technique. *J Spinal Disord* 2001;14:118-124.
41. Lippitt AB: Recurrent subluxation of the sacroiliac joint: Diagnosis and treatment. *Bull Hosp Jt Dis* 1995;54:94-102.
42. Rand JA: Anterior sacro-iliac arthrodesis for post-traumatic sacro-iliac arthritis: A case report. *J Bone Joint Surg Am* 1985;67:157-159.
43. Waisbrod H, Krainick JU, Gerbershagen HU: Sacroiliac joint arthrodesis for chronic lower back pain. *Arch Orthop Trauma Surg* 1987;106:238-240.